ONYCHOSCOPE

Nail society of India

www.nailsocietyofindia.com

Official Newsletter of NSI

Volume 10, Issue 2, Aug 2021

From the Editor's Desk;

Even though our world continues to be rocked for the second consecutive year by the unprecedented global pandemic of COVID-19, life has been restructuringin more ways than one. We in India witnessed a particularly savage resurgent attack in the months of April-May 2021. The nation, especially the health care workers were all hands on deck for a long time to ward off the effects of the second wave. We salute all our front-line workers for their dedication and relentless hard-work. We also fondly remember colleagues snatched away by cruel hands of destiny.

With the resumption of normalcy in many fields, we hereby bring to you next issue of Onychoscope. Though this issue is delayed by a month due to unavoidable circumstances, we have put in all efforts to make it as interesting and informative as the previous issues. It carries the invited faculty article by Dr Archana Singal, our founder President, who shares her experience on a common yet difficult problem "Trachyonychia".

Due to ongoing restrictions on travel and conferences, NSI this year has initiated a unique online "Skill Based CME Series" under the able leadership of Dr Sushil Tahilaini, President NSI. These CME'S are designed as 3 hour capsule courses aimed at transmitting one particular skill as a theme for that CME. This issue also reports on the first two CME's conducted on Onychoscopy and Nail Biopsy/ Histopathology in June and July 2021, respectively. The reports have been penned by Dr Deepak Jakhar. We hope our readers find the summaries informative, and also join us for future CME's which are free to register and attend. On popular demand, we are in the process of arranging a retelecast of the CME Recordings. The dates will be shared on our website and with our members shortly. The next CME on Ingrown nail management is being held on 28th August, 2021. Prominent international experts will be joining this one.

This issue includes our other regular features as well. What's new in Onychology has been meticulously prepared by Dr Shikha Bansal. We have an interesting Photo-quiz by Dr Sheetal Yadav. Challenging crossword- the Nail Maze has been contributed by Dr Sushobhan Saha. Please send in your responses and feedback at nailsocietyofindia@gmail.com

For the 2nd time in succession, ONYCHOCON-2021 (Annual National Conference of NSI) will be organised in an e-format. This is the 10th ONYCHOCON and preparations are underway to mark this landmark event in the history of NSI. It will be held on 13-14th November, 2021. It will feature Free and Award Paper sessions and the regular Nail Quiz. This year, we will be launching the NSI Thesis Awards as well. We welcome our readers and all nail enthusiasts to join NSI and contribute to our efforts towards advancing onychology. Please visit our website www.nailsocietyofindia.com for more details and updates.

Wishing for safer and healthier time ahead for all humanity! Meanwhile, we attempt to make the best of the new normal and continue to help and educate each other.

Dr Chander Grover

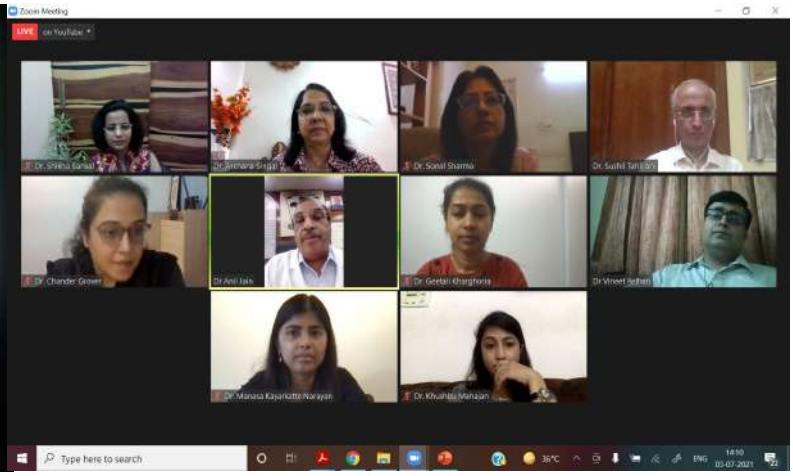

Trachyonychia

Archana Singal
MD, FAMS
Director Professor & HOD
University College of Medical Science, New Delhi, India
Head of Dermatology, Faculty of Medical Sciences (FMS), University of Delhi
Founder President NSI (2012-2020)
archanasingal@gmail.com

Trachyonychia is a common morphological entity pertaining to the nail unit and characterized by rough, lustreless nails with excessive longitudinal ridging. It is more commonly seen in children. Trachyonychia is popularly referred to as 'Twenty Nail Dystrophy of the Childhood (TND)' which is misleading because any number of nails may be involved and not necessarily 20 nails. Even the disease severity may vary in different nails. In addition, the nail lesions are not confined to the paediatric age group and can occur in any age. The original French term was 'Sand blasted nails', as the appearance was likened to the nails being rubbed with sand paper. Other synonyms include 'Sandpapered Nails' and 'Rough Nails'.

Clinical Features- Trachyonychia was estimated to constitute 1.5% of population consulting for nail disorders in a cohort. The maximum incidence has been observed in the age group of 3 to 12 years. Both male and females are equally affected. Fingernails are involved much more often than toenails. Two clinical forms exist;

a) **Opaque trachyonychia** - the more severe type and characterized by rough sand blasted nails (Figure 1 and 2). Co-existent koilonychia may be present

b) **And less severe shiny trachyonychia** - characterized by shiny, opalescent nails with numerous pits **(Figure 3).** This variant has higher association with alopecia areata

The nail plate may be thickened or thinned. Cuticles may also be thickened and ragged.

The combination of both features presenting as a mixed variant is also reported which may show superficial scaling of the nail plate, hyperkeratosis of the cuticles, koilonychia and onychoschizia.
Associations: Trachyonychia can be idiopathic or manifestation of a heterogenous group of dermatologic and non-dermatologic diseases.

a) **Dermatological diseases** - Alopecia areata, Lichen panus, Vitiligo and Psoriasis are common associations. Others include Ichthyosis vulgaris, Atopic dermatitis, Incontinentia pigmenti and Pemphigus etc. Alopecia areata is the most frequently associated with trachyonychia, therefore it is mandatory to look for it in all the cases.

b) **Non-dermatologic diseases** associations with trachyonychia remain uncommon and include Immunoglobulin A deficiency, Amyloidosis, Sarcoidosis, Immune thrombocytopenic purpura, Downs syndromeand Autoimmune hemolytic anemia.

Diagnosis - Diagnosis of trachyonychia is mainly clinical and does not necessitate laboratory workup. However, a standard evaluation protocol should be followed in all patients.

1. A detailed personal and family history is to be obtained for skin and systemic diseases.

2. Examinationof skin, hair and mucosae is warranted to identify associated alopecia areata or skin andmucosal signs ofpsoriasis and lichen planus.

3. Keeping other causes of nail dystrophy in mind, a nail clipping must be taken in all cases which is a non-invasive procedure. The nail clipping should be subjected todirect microscopic examination in KOH, to look for fungal elements and/or nail plate histology (with PAS staining)as onychomycosis is a close differential diagnosis.

Figure 1

Figure 2

Figure 3

4. **Histopathology-** Nail unit biopsy is not performed in trachyonychia to confirm the diagnosis. Histology is required only to delineate the underlying specific diagnosis or when the clinical diagnosis is ambiguous . It may offer clues to other underlying pathology e.g.; histological changes of nail psoriasis may be present in a patient diagnosed clinically as idiopathic trachyonychia.

Focal spongiotic inflammation of the nail matrix is reportedly the distinctive histological feature of idiopathic trachyonychia. Based on this finding, it may be proposed that idiopathic trachyonychia may be a subgroup of endogenous eczema limited to the nail matrix. Trachyonychia due to nail lichen planus or psoriasis will show respective findings on histology.

Disease course and prognosis- Trachyonychia is a benign, non-scarring condition of the nail unit, even if seen in association with lichen planus. Trachyonychia tend to resolve spontaneously with time in majority of the patients irrespective of the age of disease onset and number/severity of nail lesions. However, it might take few years for changes to resolve completely.

Management (Box 1 and Figure 4):

Trachyonychia is mainly a cosmetic concern as it is a non-scarring entity with a potential of complete spontaneous regression in majority. Therefore, counselling and reassurance of the parents is extremely important. 'Wait and watch policy' should be advocated in children as they tend to have a shorter disease course as compared to adults. Clinicians should evaluate thoroughly for co-existent dermatologic and systemic diseases.

Many parents request for treatment as the nail lesions may affect the quality of life adversely. Therefore, in addition to counselling, various topical and systemic treatment modalities have been used. However, there is no single evidence-based medical treatment for trachyonychia.

Box 1- Treatment modalities for Trachyonychia	
Conservative Counselling Emollients Nail paint (camouflage) **Topicals** Potent steroid ± occlusion Calcipotriol+ Betamethasone Tazarotene	**Systemic therapy** Acitretin Cyclosporine Oral steroid mini-pulse Chloroquine **Intra-matricial** Inj Triamcinolone (5mg/ml) **PUVA therapy**

Frequent use of emollient should be advised to improve the nail surface texture in opaque trachyonychia and nail polish to improve appearance in shiny trachyonychia.

FIGURE LEGENDS

Fig 1: Opaque trachyonychia in an adult male; nail have longitudinal ridging

Fig 2: Opaque trachyonychia in a child; note the associated koilonychias.

Fig 3: Shiny trachyonychia in a patient with Alopecia areata (Ophiatic variant)

Fig 4: The treatment algorithm for Trachyonychia

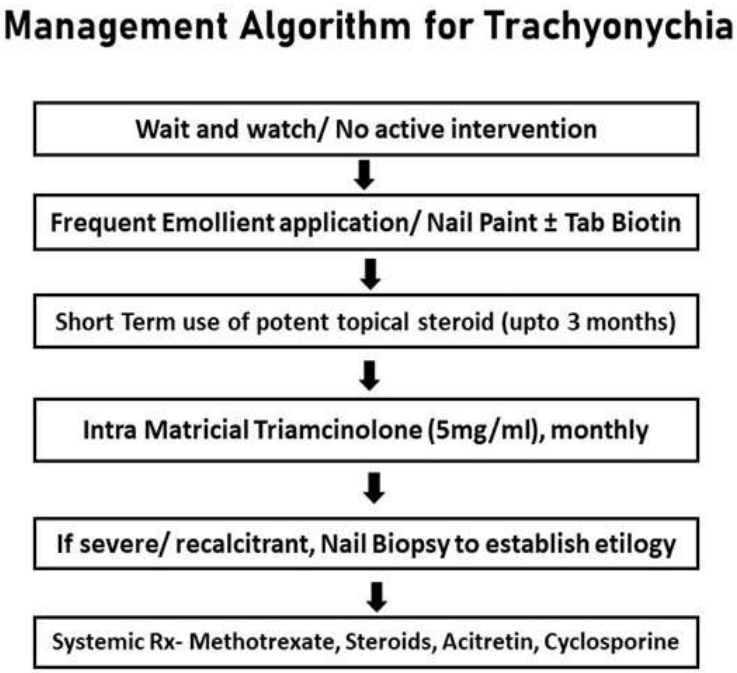

Figure 4

PHOTO QUIZ

A 7-year-old girl presented to the dermatology outpatients with a painful growth under the right thumb nailfor the past 1.5 years. She had moderate pain and difficulty in carrying out day to day activities in addition to the deformed nail. Patient gave history of a door-crush injury to the right thumb 8-months back. Two months following the injury, her mother noticed a progressively enlarging growth underneath the thumbnail. On examination, well defined distinct almost vertically oriented, thickened, lustreless nail plate was seen the proximal extent of which could not be seen (Fig 1). X ray of the digit revealed no bony abnormality

Q1 What is your diagnosis?
Q2 How would you like to manage this case?

Figure 1: A hard growth underneath the normal nail plate with distal onycholysis

Answers on page number 8

Conference Report

NSI Skill Based CME Series 2021

Amidst the prevailing COVID-19 situation, Nail Society of India (NSI) decided to hold Skill based CME series to help its members in upgrading their skills in various aspects of onychology. The principle behind these skill based CME series was to give live demonstration on various topics in addition to the theoretical aspects. These virtual CME's were available for viewing upon online registration done free of any charges. These CME's were supported by an educational grant from Linux Derma Sciences.

NSI Skill Based CME on Onychoscopy 5th June, 2021

The first CME in this series was on the topic: 'Onychoscopy'. The master of the ceremony Dr Khusbhu Mahajaninitiated the proceedingswith welcome remarks from Dr Sushil Tahiliani, President, NSI who briefed the delegates about the objectives behind starting these Skill based CME series. The objective of the Onychoscopy CME was to provide an overview about the various type of dermatoscopes used, their advantages and disadvantages when used for nails, the utility of onychoscopy in facilitating diagnosis of infective and non-infective disorders, intraoperative applications of onychoscopy and also to provide a better understanding of clinico-onychoscopic correlation of various findings.

The first session was moderated by Dr Deepak Jakhar. It was a live demonstration session with Dr Arzoo Mishra demonstrating the various components of a videodermatoscope and how it differs from a hand-held dermatoscope. Dr Vishal Gauravthen showed how to use a videodermatoscope while doing onychoscopy on various parts of the nail unit. This was followed by the demonstration of a hand-held dermatoscope where the various aspects of the device as well as it's utility in onychoscopy was discussed by Dr Jayashree Puravoor. The live demonstration was concluded with a brief presentation on the basics of onychoscopy by Dr Deepak Jakhar where he discussed the flow of onychoscopy procedure and onychoscopic images of nail unit.

The next session was a series of talks meant to illustrate onychoscopic signs indicative of various nail disorders.

Dr Balachandra Ankad discussed about the utility of microscope in non-infective nail disorders like nail psoriasis, nail lichen planus and longitudinal melanonychia.

He discussed the utility of examining distal onycholysis to differentiate the cases of nail psoriasis, onychomycosis and traumatic onycholysis. Dr Yasmeen Bhat discussed about the utility of onychoscopy in infective nail disorders. She discussed the various onychoscopy features in different types of onychomycosis,

warts, pseudomonas etc. **Dr Ishmeet Kaur** discussed about the role of intraoperative onychoscopy in various nail pathologies and how it can be utilised for selecting the site of biopsy and complete excision of the various nail tumours.

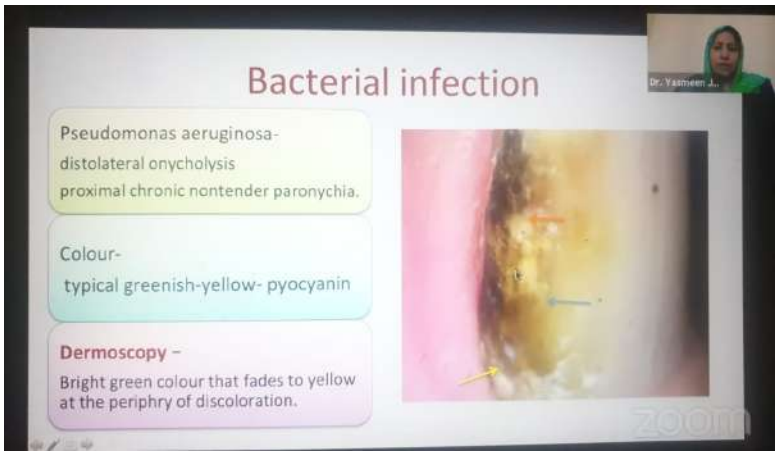

Thereafter, researchers presented their findings in specific nail diseases.

Dr Manasa KN told that percentage positivity for diagnosing onychomycosis in decreasing order was direct microscopic examination with potassium hydroxide followed by spiked pattern, subungual hyperkeratosis, distal irregular termination on onychoscopy. **Dr Ankita Chauhan** shared that fuzzy lunula was a novel onychoscopic feature in her research on nail psoriasis, in addition to the known features like pitting, subungual hyperkeratosis, onycholysis dotted capillaries. **Dr Geetali Khargoria** said onychoscopy helps in identifying features of nail LP not otherwise visible on naked eye, in the form of linear nail bed dyschromia, splinter haemorrhages, erythematous lunula, flame-shaped lunula, and yellow lunula. **Dr Jayashree Puravoor** presented onychoscopy findings in glomus tumor as localized structureless erythema interspersed with bluish and patchy whitish areas (nail bed glomus) and a "candy-cane appearance" (nail matrix glomus).

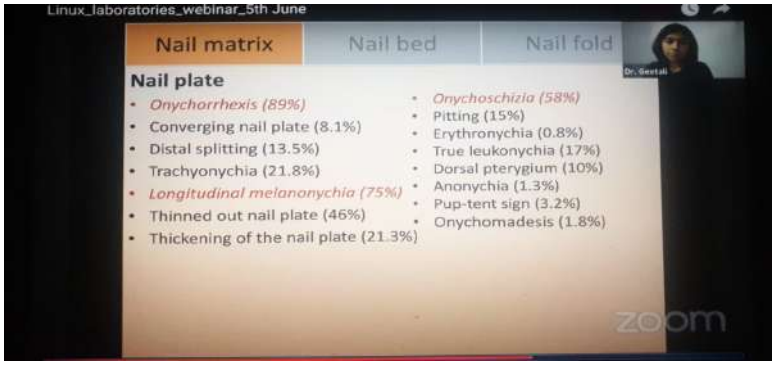

The last session was a panel discussion on 'Clinic-onychoscopy correlation: How it helps?'. It was moderated by Dr Chander Grover and panellists included **Dr Archana Singal, Dr Balachandra Ankad, Dr Deepak Jakhar, Dr Jayashree Puravoor and Dr Yasmeen Bhat. Dr Chander Grover** discussed very interesting nail disorders along with their onychoscopy and histopathology images, to highlight how much onychoscopy contributed towards the final diagnosis.

The CME was concluded by Dr Vineet Relhan, Vice President, NSI who thanked all the faculty members and delegates for their active participation. A total of 450 delegates from all over India and abroad registered for the first CME.

NSI Skill Based CME on Nail Biopsy and Histopathology 3rd July, 2021

The second NSI Skill based CMEwas jointly organised with the department of Dermatology & STD, UCMS & GTBH to commemorate the golden jubilee year of University College of Medical sciences. It was held on the topic: 'Nail Biopsy and Histopathology'. Nail Biopsy is a lesser utilised diagnostic modality, as introduced by the master of ceremony, **Dr Khusbhu Mahajan. Dr Sushil Tahiliani**, President, NSI and **Dr Archana Singal**, Founder President, NSI welcomed the delegates, emphasising the need for acquiring this skill. Dr Archana talked briefly about the Department of Dermatology and STD at UCMS and the work done by it in the field of nail biopsy. **Dr A K Jain, Principal, UCMS** addressed the delegates, highlighting the high quality research being engaged in by UCMS including the department of dermatology, over the years. He praised the organisation of such free to access learning initiatives.

The first session started with **Dr Vineet Relhan** discussing the importance of knowing the basics of nail unit anatomy, along with the various procedural requirements and precautions for nail biopsy. **Dr Shikha Bansal** then demonstrated the various factors to be taken into account while choosing a site for nail biopsy. She showed representative images of dystrophic nails highlighting from where the biopsy will give maximum diagnostic yield. Additionally, she showed the procedure of punch biopsy in nail unit. Thereafter **Dr Chander Grover** demonstrated procedures for nail biopsy other than the punch biopsy.

This included videos of nail bed excision biopsies as well as different types of nail matrix biopsies. Dr Sonal Sharma then discussed the challenges faced by pathologists in processing the nail tissue, especially the nail plate. She showed the various processing and fixing techniques for nail unit samples. In addition, she showed various histopathological features of various nail pathologies.

The next session highlighted the research findings on nail biopsy and histopathology in various nail diseases done over the years in UCMS. Dr Subuhi Kaul discussed the histological features of nail psoriasis. She reported that the feature found most frequently were hyperkeratosis with parakeratosis, followed by neutrophilic infiltration of nail bed epithelium and hypergranulosis. Dr Geetali Kharghoria described hypergranulosis of nail matrix and bed epithelium, followed by sawtooth acanthosis and lichenoid band to be the most common histopathological features of nail lichen planus. She also reported novel histopathological findings, especially the 'frayed nail plate'. **Dr Manasa KN** presented the various histopathological features of onychomycosis.

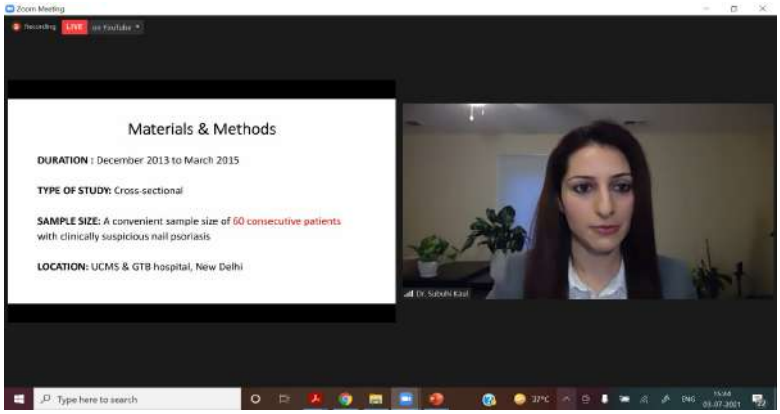

The last session was again a panel discussion on 'Clinico-pathological correlations: How nail biopsy helps!'. It was moderated by Dr Archana Singal. The panelists included Dr Sushil Tahiliani, Dr Sonal Sharma, Dr Vineet Relhan, Dr Chander Grover, and Dr Shikha Bansal. This was an interesting session showcasing difficult to diagnose nail cases and their histopathological features which contributed towards management. Practical points like the importance of demonstrating fungal invasion or choosing appropriate site for biopsy were suitably illustrated. The CME concluded with closing remarks by Dr Chander Grover, Honorary Secretary, NSI who encouraged delegates to join NSI and also announced the schedule for the next CME.

Dr Deepak Jakhar, Dr Chander Grover

EXCERPTS FROM NAIL LITERATURE

NAIL: WHAT'S NEW?

Ricardo JW, Lipner SR. Air cooling for improved analgesia during local anesthetic infiltration for nail surgery. J Am Acad Dermatol. 2021 May;84(5):e231-e232.

Adequate, effective nail unit anaesthesia is essential for performing any nail surgery. Ricardo et al described the use of an air cooling device for direct cold application over anaesthesia site. In this technique, they used a thin tube attached to a compressor system used to deliver a stream of cold air at a flow rate of 500-1000 L/min at -30 degree C.

Conventionally, to improve pain tolerance over local anesthesiasite;ice, chilled saline bags, gel or liquid nitrogen are utilised prior to injecting; efficacy of these methods is dependent on the topography of the area to be treated. They may also physically interfere with infiltration of anaesthetic agent. Utilisation of this technique helps in. minimising pain during local anaesthetic infiltration.

Comment: Many patients describe nail anaesthesia as the most painful part of their nail surgery experience, primarily because of the infiltration of local anaesthetic agent, newer technique to reduce pain during local anaesthesia infiltration can alleviate patients anxiety during the procedure.

Sharma P,Sharma S, Kaul Murthy S, Singal A, Grover C. Comparison of four softening agents used on formalin-fixed paraffin-embedded nail biopsies with inflammatory disease.J Histotechnol .2020 ;43:3-10

Nail plate is a hard structure, requiring softening as an important step in order to prevent splitting of keratotic tissue during sectioning. This essential step prevents tissue shattering and subsequently leads to improvement of quality of sections. Sharma et alin their study compared softening agents on nail biopsy specimens, that were formalin fixed and embedded in paraffin. They treated the trimmed blocks with distilled water (control), 30% potassium hydroxide (KOH), hair removal cream and fabric conditioner. The authors concluded that fabric conditioner and hair removal cream are effective keratin softeners, but hair removal cream is not good for cases where serial sectioning is required.

Comment:Post nail biopsy procedure ,sample processing is an important step that determines the diagnostic yield from a nail biopsy. This recent innovationin nail softening methods, is aimed at improving the diagnostic outcomes of nail biopsies.

Kaur I, Jakhar D, Misri R. Hangnails: Paste them back. Pediatr Dermatol. 2020 Jan;37(1):255-256

Hangnails is a painful condition seen commonly in paediatric age group. It refers to small pieces of torn skin, surrounding the nail unit. Management involves cutting the excessive skin. However a small part of hang nail still tends to remain and causes discomfort to the patient. Kaur et aldescribed theuse of a liquid bandage in the form of 2-octyl cyanoacrylate surgical glue, otherwise commonly used for closing incisions, as a topical agent. They used it to paste non-infected hangnails back into its original position. The patient gets instant relief and condition improves over time.

Comment: Use of easily available surgical glue for management of hang nails can provide a simple solution to this painful condition .

Ramesh S, Shenoi SD, Nayak SUK. Comparative efficacy of 10% sodium hydroxide, 88% phenol, and 90% trichloroacetic acid as chemical cauterants for partial matricectomy in the management of great toe nail onychocryptosis. J Cutan Aesthet Surg 2020;13:314-8.

Partial nail avulsion with lateral chemical matricectomy is the treatment of choice for ingrown toe nail. Ramesh et alcompared three agents for chemical matricectomy for management of ingrown toe nail. They recruited 15 patients, which were divided into three groups, to evaluate the efficacy of 10% NaOH (1 min), 88% Phenol (3 min) and 90% tri-chloro aceitic acid (TCA) (3 min). Weekly follow-up evaluation of three parameters- pain, oozing and wound healing, found TCA to be an efficacious cauterant with advantage of lesser post-operative pain and faster healing.

Comment:Phenol has been used commonly for chemical cauterization ,however there is collateral tissue damage with prolonged post-operative tissue necrosis and serous drainage. Hence ,use of TCA as an effective agent for chemical matricectomy can be utilised for patients benefit.

Kandpal R, Arora S, Arora D. A study of Q-switched Nd:YAG laser versus itraconazole in management of onychomycosis. J Cutan Aesthet Surg 2021;14:87-94.

Onychomycosis is a common nail condition that might require prolonged usage of systemic antifungals to achieve a clinical cure.Kandpal et alcompared the efficacy of Q-switched Nd: YAG Laser (1064 nm) with itraconazole in the management of onychomycosis. Patients were divided into two groups, with the first group receiving 12 weekly sessions of the laser. Second group was administered itraconazole 200 mg twice daily for 1 week per month for 3 months. The authors found a faster clearance in laser group with statistically significant improvement. Mycological cure was also higher in Laser group with non-dermatophytes responding better to laser therapy as compared to itraconazole pulse. The authors concluded that laser is more effective in clearing the nails at 3 months of treatment, and both treatment options are efficacious at 1 year follow up.

Comment:Onychomycosis is a common nail condition. Slower nail growth, drug resistance and side-effects to systemic antifungals are the major limiting factors in ensuring successful treatment outcomes. Q-Switched Nd:YAG Laser has been FDA approved in management of onychomycosis; however, many innovative combinations and techniques have been evaluated regarding their use in nail diseases.

Dr.Shikha Bansal
Professor
Department of Dermatology
VMMC and Safdarjung Hospital
New Delhi

NAIL MAZE



Across

1. Nail tumour manifesting as ' bleeding nail' while clipping
4.'Turtle back' shape of nails is seen in this lysosomal storage disorder
5.Term used to describe abrupt keratinization without a distinct granular layer
6. Topical nail therapeutic agent causing yellow-brown discolouration of nail plate
7 Rare, severe variant of nail lichen planus that may present with nail degloving
8. Genus of fungal organism causing both onychomycosis and mycetoma
9.Painful horn of distal median bed of great toenail

Down

1. Behavioral disorder characterized by biting of nails to gain Pleasure from pain
2. Gene critical for nail development, absence of which causes anonychia
3. Named classification system of onychocryptosis

Send in your answers to nailsocietyofindia@gmail.com

Compiled by:
Dr Sushobhan Saha
Senior Resident
Department of Dermatology and STD
UCMS and GTB Hospital
Delhi, India

Answer to Photo quiz

Ans 1- This is a case of onychoheterotopia (ectopic nail) where there is continuous growth of nail tissue at site other than primary nail unit. It can be acquired; following trauma due to traumatic implantation of germinal matrix onychocytes at an ectopic site or congenital (ectopic existence of germ cells, nail of a rudimentary polydactyly). Post traumatic ectopic nail seems to the plausible explanation in our case Ectopic nail clinically presents as an extra nail as a small outgrowth or double nail which is usually asymptomatic but can be associated with pain, secondary infection and deformity of the underlying joint or bone by impeding intramembranous ossification. Differential diagnosis to be considered cutaneous horn, rudimentary polydactyly, foreign body and split nail deformity.

Figure 2: Deformed ectopic nail aligned vertically

Figure 3: Ectopic nail plate matrix (black arrow) that was destroyed by radio frequency ablation

Ans 2- The mainstay of treatment is surgical excision of the ectopic nail along with the ectopic nail matrix and primary closure of defect. Rarely it can be associated with recurrence. In our case, surgical intervention was undertaken to explore the origin of the ectopic nail (Figure 2). The ectopic nail was then removed to exposed the matrix that lay linearly in the nail bed region, 2-mm distal to the proximal nail fold (Fig 3, black arrow). This ectopic matrix was destroyed by radiofrequency ablation. There was normal growth of primary nail plate and no recurrence was noted.

Contributed by:

Sheetal Yadav Senior resident
Archana Singal Director Professor & HOD
Department of Dermatology and STD' UCMS and GTB Hospital Delhi, India

Answer Key Volume 10, Issue 1 January 2021

1) Culture
2) Trichophyton
3) Onychomycosis
4) Candida
5) Amorolfine
6) Itracanazole
7) KOH
8) HIV
9) Psoariasis
10) Glomus tumor
11) Pitting
12) Beau's line

No completely correct entries were received this time.

Editorial Board Members

Dr. Archana Singal

Dr. Chander Grover

Dr. Shikha Bansal